EHF SCIENTIFIC CONFERENCE 2015

ESSKA

3rd European Handball Federation (EHF)
Medical Scientific Conference 2015

# GUIDELINES AND RETURN TO SPORT AFTER MENISCAL REPAIR AND CHONDRAL PROCEDURES

**G.L. CANATA, V. CASALE**

**Centre of Sports Traumatology,**
**Koelliker Hospital, Torino, Italy**
**Institute of Sports Medicine, Torino, Italy**

# HANDBALL MECHANICS

**rapid changes of movements,**

**jumps with hard landings,**

**collisions between players**

**REPETITIVE KNEE AND SHOULDER JOINT STRESS.**

**The risk of injuries is much higher during the match than in training.**

Bere T, Alonso JM, Wangensteen A, Bakken A, Eirale C, Dijkstra HP, Ahmed H, Bahr R, Popovic N. **“Injury and illness surveillance during the 24th Men's Handball World Championship 2015 in Qatar”** Br J Sports Med. 2015 Sep;49(17):1151-6

# INJURIES IN HANDBALL ATHLETES

**knee and the ankle** **ACUTE INJURIES,**

**lower leg and shoulder** **OVERUSE LESIONS.**

Bere T, Alonso JM, Wangensteen A, Bakken A, Eirale C, Dijkstra HP, Ahmed H, Bahr R, Popovic N. **"Injury and illness surveillance during the 24th Men's Handball World Championship 2015 in Qatar"** Br J Sports Med. 2015 Sep;49(17):1151-6

**ACUTE INJURY OR CHRONIC MICROTRAUMA: PROGRESSIVE CARTILAGE DEFECTS**

# INJURIES IN HANDBALL ATHLETES

**ACL lesions are the most frequent injuries, especially in women (16%, against 9% for women volleyball players or 4,4% for women basketball players)**

Rosa BB, Asperti AM, Helito CP, Demange MK, Fernandes TL, Hernandez AJ **"Epidemiology of sports injuries on collegiate athletes at a single center"** Acta Ortop Bras. 2014;22(6):321-4

**The type of training, exercises and movements during the matches are directly related to injuries**

# CHONDRAL INJURIES IN ATHLETES

HIGH DEMAND PIVOTING ATHLETES:

UP TO 12 FOLD INCREASED RISK OF KNEE OSTEOARTHRITIS

DRAWER S, FULLER CV. Br J Sports med 2001;35:402-408

ACUTE INJURY OR CHRONIC MICROTRAUMA: PROGRESSIVE CARTILAGE DEFECTS

# CHONDRAL INJURIES IN ATHLETES

- **FOCAL FULL THICKNESS CHONDRAL DEFECTS 36%**
  - **LOCATION: - PATELLO FEMORAL 37%**
    **- FEMORAL CONDYLES 35%**

FLANIGAN DC, BROPHY RH. Med Sci Sports Exerc 2010;42:1795-1801

- **PROFESSIONAL BASKET PLAYERS:**
  - **CARTILAGE ABNORMALITIES 89%**

WALCZAK BE et al. Knee Surg 2008;21:27-33

# CHONDRAL KNEE LESIONS

•**FOCAL LESIONS**: well delineated defects, more often caused by trauma or diseases like osteochondritis dissecans, osteonecrosis, Paget disease, acromegaly or haemophilia.

•**DEGENERATIVE DEFECTS**: less demarcated lesions, ususally related to ligament instability, meniscal injuries, malalignement or osteoarthritis.


➢Craig W, David JW, Ming HZ **"A current review on the biology and treatment of the articular cartilage defects (part I & part II)"** J Musculoskelet Res . 2003;7:157–181

➢Hunziker EB. **"Articular cartilage repair: basic science and clinical progress. A review of the current status and prospects"** Osteoarthritis Cartilage. 2002;10(6):432-63.

# CHONDRAL KNEE LESIONS OUTERBRIDGE CLASSIFICATION

- **GRADE 0** = normal articular cartilage
- **GRADE 1** = softening, blistering or swelling of cartilage
- **GRADE 2** = partial thickness fissures < 1 cm diameter
- **GRADE 3** = full thickness fissures until subchondral bone, > 1 cm diameter
- **GRADE 4** = exposed subchondral bone

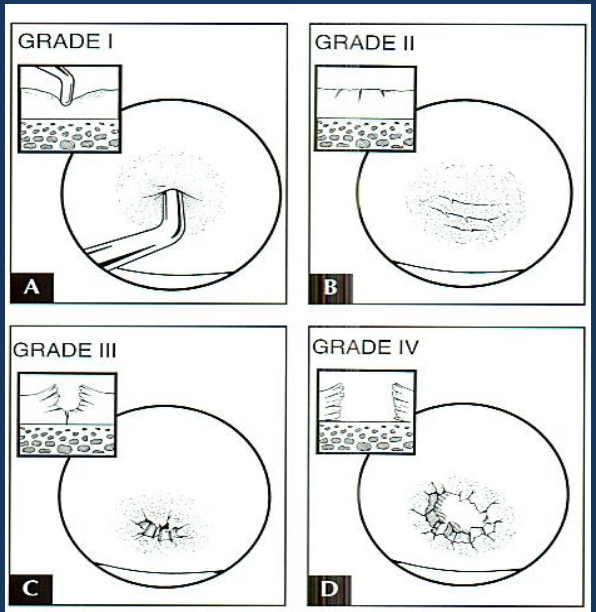

Fig 4: Outerbridge classification of cartilage injuries. A: GI; B: GII; C: GIII; D: GIV.

# ASYMPTOMATIC LESIONS

- EVEN GRADE 3 OR 4 CHONDRAL LESIONS OBSERVED IN ACL SURGERY MAY STILL BE SILENT AT A 10-15 YEAR FOLLOW UP

Widuchowsky W et al Am J Sports Med 2009

- PATELLOFEMORAL CHONDRAL LESIONS IN BASKETBALL PLAYERS : UP TO 41% NO SYMPTOMS

Kaplan LD et al. Arthrtoscopy 2005

# MENISCUS AND CARTILAGE
# A SYNERGIC FUNCTION

- **IMPORTANT SHOCK ABSORBERS**
- **STABILIZERS**
- **ASSOCIATED INJURIES IN HIGH IMPACT SPORTS**
- **RISK OF PROGRESSIVE JOINT DEGENERATION**


- Kessler MA, Glaser C, Tittel S, Reiser M, Imhoff AB **"Volume changes in the menisci and articular cartilage of runners: an in vivo investigation based on 3-D magnetic resonance imaging"** Am J Sports Med. 2006 May;34(5):832-6
- Subburaj K, Kumar D, Souza RB, Alizai H, Li X, Link TM, Majumdar S **"The acute effect of running on knee articular cartilage and meniscus magnetic resonance relaxation times in young healthy adults"** Am J Sports Med. 2012 Sep;40(9):2134-41.


**REPAIR WHENEVER POSSIBLE !!**

# THERAPY?

## BIOLOGICAL
## BIOMECHANICAL

EDUCATION
LOAD MODIFICATION
HEALING PROMOTION
ACTIVITY MODIFICATION
SURGERY

# ASSOCIATED MENISCAL REPAIR

- **POSTOPERATIVE RESTRICTIONS TO PROTECT THE HEALING TISSUES**
- **Healing progression depends on: age, associated injuries, injury severity**

**size and location of the meniscal tear**

MEDIAL MENISCUS TEARS 37%- ACL LESIONS 36%
Widuchowsky W et al . Knee. 2007;14:177-182

# REHABILITATION

## PROCEDURES EASING THE HEALING PROCESS

**Influenced by:**

- AGE
- MORPHOLOGY, BMI AND PHYSICAL QUALITIES
- TYPE AND LEVEL OF SPORT
- PSYCHOLOGY
- LESION SEVERITY AND LOCATION
- CONCOMITANT PATHOLOGIES
- SURGICAL PROCEDURE

# REHABILITATION GUIDELINES
# MENISCAL REPAIR
## PHASE I: FROM SURGERY TO 4 W

- GRADUAL WEAN FROM 2 CRUTCHES TO FWB
- KNEE BRACE LOCKED FOR WB
- FLEXION LIMITATION- SITTING HEEL SLIDES
- PAIN FREE GAIT – NO EFFUSION
- QUADRICEPS SETS – HEEL PROP
- STRAIGHT LEG RAISES – ANKLE PUMPS
- ABDOMINAL ISOMETRICS - CORE STABILITY

# REHABILITATION GUIDELINES
# MENISCAL REPAIR
## PHASE II: AFTER 4/6 W

- PROGRESSION TO FWB – NORMAL GAIT
- FLEXION LIMITATION PAST 60°
- PAIN FREE GAIT – NO EFFUSION - GAIT DRILLS
- STATIONARY BIKE- SWIMMING
- QUAD EXERCISES 0-60° - LEG PRESS
- CORE STABILITY – PROPRIOCEPTION
- STANDING TOE RAISE – WALL SLIDES

# REHABILITATION GUIDELINES
# MENISCAL REPAIR
## PHASE III: 3/4 MONTHS AFTER SURG

- PROGRESSION TO PAIN FREE IMPACT
- AGILITY EXERCISES- PROGRESSIVE VELOCITY
- PAIN FREE – NO EFFUSION –
- LIGHT SPORTS SPECIFIC DRILLS
- CORE STABILITY – PROPRIOCEPTION
- WEIGHT TRAINING
- RESTORATION OF DYNAMIC NEUROMUSCULAR CONTROL

# REHABILITATION GUIDELINES
# MENISCAL REPAIR
## PHASE IV: 4/5 MONTHS AFTER SURG

- PROGRESSIVE RUNNING
- AGILITY RUNNING PROGRAMS
- PAIN FREE – NO EFFUSION –
- CORE STABILITY – PROPRIOCEPTION
- RESTORATION OF DYNAMIC NEUROMUSCULAR CONTROL
- PROGRESSIVE RETURN TO SPORTS

# MENISCUS AND CARTILAGE ASSOCIATED LESIONS

- **At the time of an ACL reconstruction, the concomitant presence of a cartilage injury and a meniscal tear negatively influences functinal outcomes, even 2 or 6 years postoperatively.**


- Cox CL, Huston LJ, Dunn WR, Reinke EK, Nwosu SK, Parker RD, Wright RW, Kaeding CC, Marx RG, Amendola A, McCarty EC, Spindler KP **"Are articular cartilage lesions and meniscus tears predictive of IKDC, KOOS, and Marx activity level outcomes after anterior cruciate ligament reconstruction? A 6-year multicenter cohort study"** Am J Sports Med. 2014 May;42(5):1058-67
- Røtterud JH, Sivertsen EA, Forssblad M, Engebretsen L, Arøen A **"Effect of meniscal and focal cartilage lesions on patient-reported outcome after anterior cruciate ligament reconstruction: a nationwide cohort study from Norway and Sweden of 8476 patients with 2-year follow-up."** Am J Sports Med. 2013 Mar;41(3):535-43

# CHONDRAL KNEE LESIONS
## TREATMENT

- <u>CONSERVATIVE TREATMENT</u>
  - small and stable lesions, mild pain
  - use of chondroprotective agents, intraarticular injections of hyaluronic acid
  - effective only if articular cartilage is still intact
  - does not prevent the progress of the damage? (Guettler JH et al. 2004)

# EXOGENOUS HYALURONIC ACID

- It stimulates de novo synthesis of hyaluronic acid
- It inhibits release of arachidonic acid, and inhibits interleukin-1α.
- It induces prostaglandin E2 synthesis by human synoviocytes.

- Recent clinical trials have evaluated the efficacy and safety of intra-articular hyaluronic acid injections.

# PRP

- Am J Phys Med Rehabil. 2012 May;91(5):411-7.**Treatment of knee joint osteoarthritis with autologous platelet-rich plasma in comparison with hyaluronic Acid**.

Spakovà T et al

autologous PRP as an effective and safe method in the treatment of the initial stages of knee osteoarthritis

# Correction of byomechanical abnormalities

Orthotic devices

Shock absorbers

Activity modifications

Weight reduction

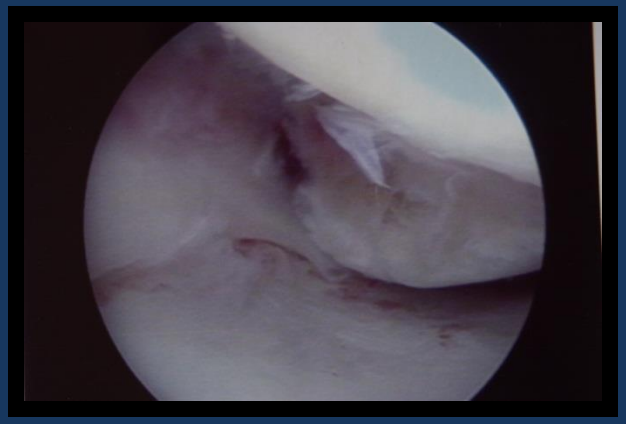

# CARTILAGE SURGERY

- **RESTORATIVE:**
  - Osteochondral autografts transfer (OATS)
  - Allograft transplantation
- **REPARATIVE:**
  - Marrow stimulation (microfractures, microdrilling , nanoperforations)
  - Chondrocyte based cartilage repair
  - Scaffolds

# CHONDRAL KNEE LESIONS
## TREATMENT

**Treatment choice depends on:**

- **patient's age**
- **cause of injury**
- **size and depth of lesions**
- **patient's activity level**
- **presence of combined defects**

Seo SS, Kim CW, Jung DW **"Management of focal chondral lesion in the Knee joint"** Knee Surg Relat Res 2011;23(4):185-196

# CARTILAGE SURGERY
## WHICH PROCEDURE?

| | |
|---|---|
| Microfractures | 43 % |
| Debridement | 31% |
| Non operative treatment | 13% |
| Allograft transplantation | 4% |
| OATS | 6% |
| Chondrocyte based cartilage repair | 3% |

Brophy RH, Rodeo SA, Barnes RP, Powell JW Warren RF **«Knee articular cartilage injuries in the National Football League: epidemiology and treatment approach by team physicians».** J Knee Surg. 2009;22:331-338

# CHONDRAL KNEE LESIONS
## SURGICAL TRATMENT

### ARTHROSCOPY

- **It may be helpful to prevent future cartilage delamination**
- **Debridement chondroplasty is possible using several techniques as curettage, paying attention not to get the cartilage damage worse**
- **Retrograde drilling**
- **Refixation of repairable fragments (trap door lesions)**

Falah M, Nierenberg G, Soudry M, Hayden M, Volpin G **"Treatment of articular cartilage lesions of the knee"** International Orthopaedics (SICOT) 2010;34:621-630

# Rehabilitation after Surgical Treatment

- Debridement

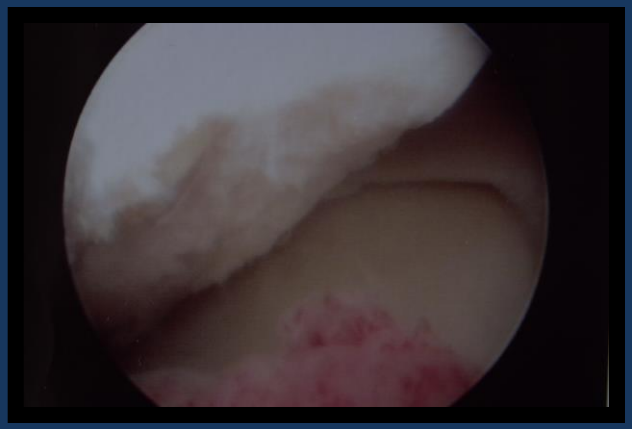

Activity modification

Improve biomechanical environment

Orthotic devices

No different rehab in ACL surgery

AVOID PAIN!

# Debridement

Levy AS, Lohnes J, Sculley S, LeCroy M, Garrett W:

Chondral delamination of the knee in soccer players.

Am J Sports Med 1996;24:634-639.

- 100% good results in soccer players at 1y fu. Fibrocartilagineous response

# AUTOLOGOUS CHONDROCYTE IMPLANTATION (ACI)

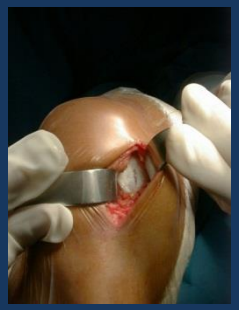

- **CELL-BASED THERAPY**
  - two-stage procedure
  - long rehabilitation
  - it causes less damages to subchondral bone plate and trabecula than other procedures
  - best candidates are patients between 15 and 55 yearsof age, with Outerbridge 3-4 stages lesions
  - complicatioins may be caused by periosteal hypertrophy, loosening of the periosteal flap and loss of cells in the joint cavity

    → a COLLAGEN MEMBRANE better than a periosteal flap

    → the use of cell seeded scaffolds ( MACI) is improving results

Dai XS, Cai YZ **"Matrix-induced autologous chondrocyte implantation addressing focal chondral defect in adolescent knee"** Chin Med J (Engl). 2012;125(22):4130-3

# MATRIX ASSOCIATED CHONDROCYTE IMPLANTATION (MACI)

RESULTS:

COMPARED TO MICROFRACTURES IN ATLETES: NO DIFFERENCE IN HIGH LEVEL FOOTBALL PLAYERS

RETURN TO SPORT :

MICROFRACTURES 8 MONTHS

MACI: 12,5 MONTHS

Kon E et al Am J Sports Med

# MARROW STIMULATION PROCEDURES

## CELL-BASED THERAPY

- **MICROFRACTURES** - most used techniques, good results
- **SUBCHONDRAL DRILLING** – good results
- **ABRASION ARTHROPLASTY** - results vary among the studies, but thy are never good to excellent

# MICROFRACTURES
# MICRODRILLING
# NANOPERFORATIONS
# RETRODRILLING

- **HIGHLY PROTECTED WEIGHT BEARING 6-8 WEEKS**
- **CPM: 1500 TIMES A DAY**
- **NO CUTTING ,TWISTING OR JUMPING SPORTS UNTIL AT LEAST 4 MONTHS**

Sledge SL **"Microfracture techniques in the treatment of osteochondral injuries"** Clin Sports Med. 2001 Apr;20(2):365-77

# OSTEOCHONDRAL AUTOGRAFT TRANSPLANTATION (OAT)

- optimal for focal lesions, less useful for degenerative defects
- one-stage procedure, unlike ACI
- it may be performed arthroscopically in case of small lesions
- shorter rehabilitation time than cell-based techniques
- the lesion is covered by hyaline cartilage

Seo SS, Kim CW, Jung DW **"Management of focal chondral lesion in the Knee joint"** Knee Surg Relat Res 2011;23(4):185-196

**BUT: ONLY A FEW STUDIES ON ATHLETES**

**Gudas R et al KSSTA 2006**

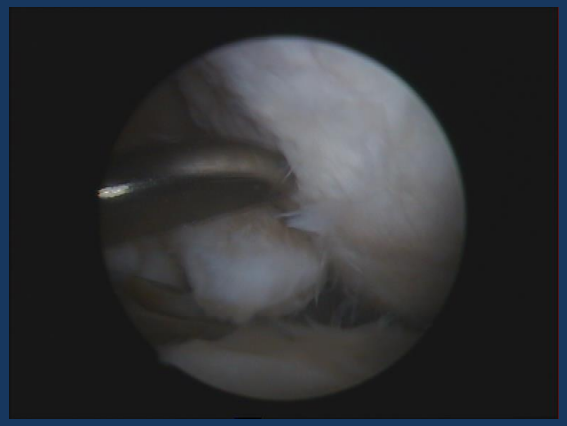

# OSTEOCHONDRAL AUTOGRAFT TRANSPLANTATION (OAT)

- TOUCH WEIGHT BEARING FOR 6 WEEKS
- HINGED KNEE BRACE 0° -90°
- STATIONARY BICYCLE EXERCISES

- RADIOGRAPHS AND MRI AT 3 AND 6 MONTHS
- SPOILED GRADIENT IMAGES AND T2 SEQUENCES

Morelli M, Nagamori J, Miniaci A **"Management of chondral injuries of the knee by osteochondral autogenous transfer (mosaicplasty)"** J Knee Surg. 2002;15(3):185-90

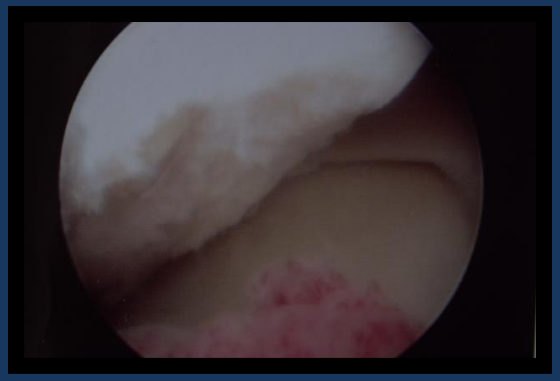

# SCAFFOLDS

- improving outcomes
- high costs
- cell-based techniques focus on reconstrucion of the superficial layer of cartilage. This technique try to modify cartilage regeneration addressing the subchondral bone
- in some cases the structure of the repaired tissue is not homogenous, subchondral bone changes as oedema and sclerosis may develope

Filardo G, Kon E, Di Martino A, Busacca M, Altadonna G, Marcacci M «**Treatment of knee osteochondritis dissecans with a cell-free biomimetic osteochondral scaffold: clinical and imaging evaluation at 2-year follow-up”** Am J Sports Med. 2013;41(8):1786-93

# CHONDROCYTE GRAFTS

- FREE ROM EXERCISES
- PROTECTED WEIGHT BEARING 6-12 WEEKS TO PREVENT DELAMINATION OR DEGENERATION OF THE GRAFT
- FULL WEIGHT BEARING BY 12 WEEKS
- CONFORTABLE WALKING BY 4 MONTHS

- TROCHLEA DEFECTS: INITIAL ROM 0° -40°

# CHONDROCYTE GRAFTS
## TROCHLEAR LESIONS

- IMMEDIATE STRIGHT LEG LIFTS, ACTIVE FLEXION, PASSIVE EXTENSION FOR THE FIRST 6 WEEKS
- NO KNEELING AND SQUATTING UNTIL 12-18 MONTHS

# CHONDROCYTE GRAFTS

- BY 4-41/2 MONTHS: NON IMPACT ACTIVITIES
- LONG DISTANCE WALKING, CYCLING, SWIMMING, CROSS COUNTRY SKIING
- RUNNING BY 9-12 MONTHS
- CUTTING SPORTS BY 12-18 MONTHS

- LARGER LESIONS TAKE UP TO 18-24 MONTHS (Pj King, 2002)

Minas T, Chiu R **"Autologous chondrocyte implantation"** Am J Knee Surg 2000;13(1):41-50

# LIMITED EBM ON REHABILITATION AFTER CHONDRAL REPAIR

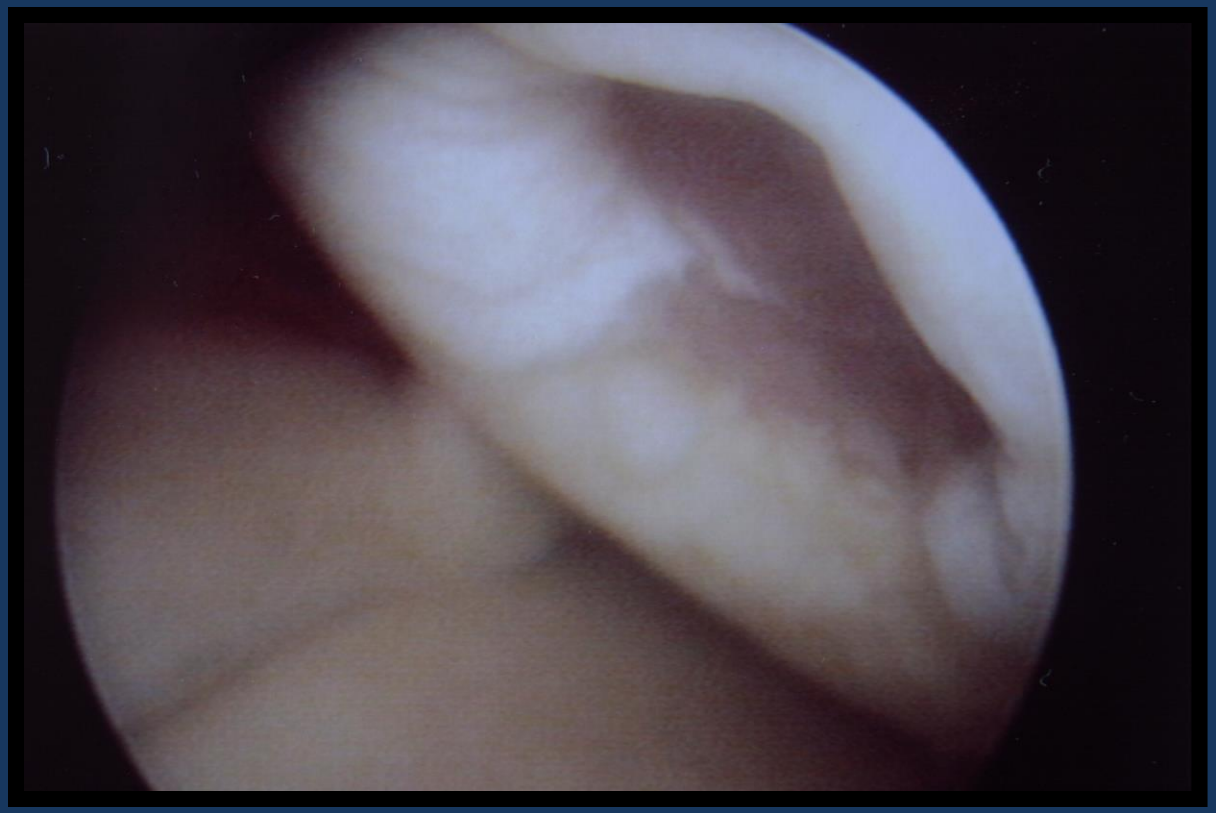

# CARTILAGE SURGERY

## RETURN TO SPORT

| | |
|---|---|
| OATS | 86-94% |
| ALLOGRAFT TRANSPLANTATION | 84% |
| MICROFRACTURES | 25-100 % |
| CHONDROCYTE BASED CARTILAGE REPAIR | 33-96% |

**MICROFRACTURES AND OATS ARE MORE EFFECTIVE IN SMALLER LESIONS**

Richter DL, Schenck RC Jr, Wascher DC, Treme G **"Knee Articular Cartilage Repair and Restoration Techniques: A Review of the Literature"** Sports Health. 2015 Oct 12 (Epub ahead of print)

# CARTILAGE SURGERY

## RETURN TO SPORT IN TOP ATHLETES MONTHS

| | |
|---|---|
| OATS | 5,5 |
| MICROFRACTURES | 7-8 |
| CHONDROCYTE BASED CARTILAGE REPAIR | 14,2 |

HARRIS JD ET AL ARTHROSCOPY 2010 Richter DL

# CARTILAGE SURGERY
## DETERIORATION WITH TIME?

ACI BETTER ?

Gudas R et al KSSTA 2006

MICROFRACTURES ?

Steadman J J Knee Surg 2006

SIZE? Better results if < 2cm and age <40 y No previous surgery

Mithofer Am J Sports Med 2006

# INJURY- SURGERY TIME

HIGHER PROBABILITY OF RETURN TO SPORT IF SURGERY PERFORMED < 1 YEAR AFTER INJURY

Mithofer Am J Sports Med 2006

# EARLY POSTOPERATIVE TREATMENT

- SPECIFIC MANAGEMENT

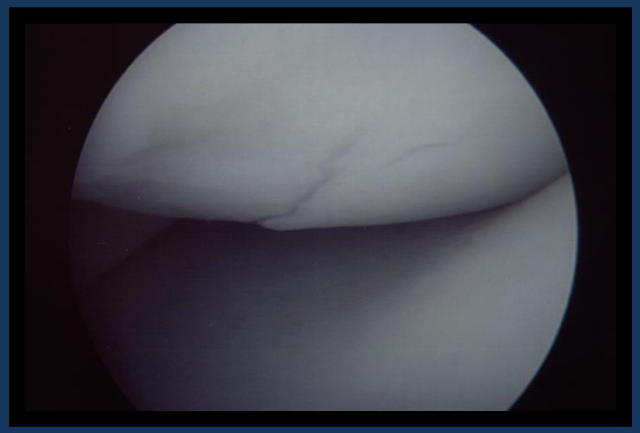

- CONDYLE LESIONS
- PATELLO-FEMORAL LESIONS

# CONDYLE LESIONS

- STRICT LIMITATION OF WEIGHT BEARING
- TOUCH-DOWN WEIGHT BEARING ALLOWED (15% BODY WEIGHT)
- IMMEDIATE MOBILIZATION

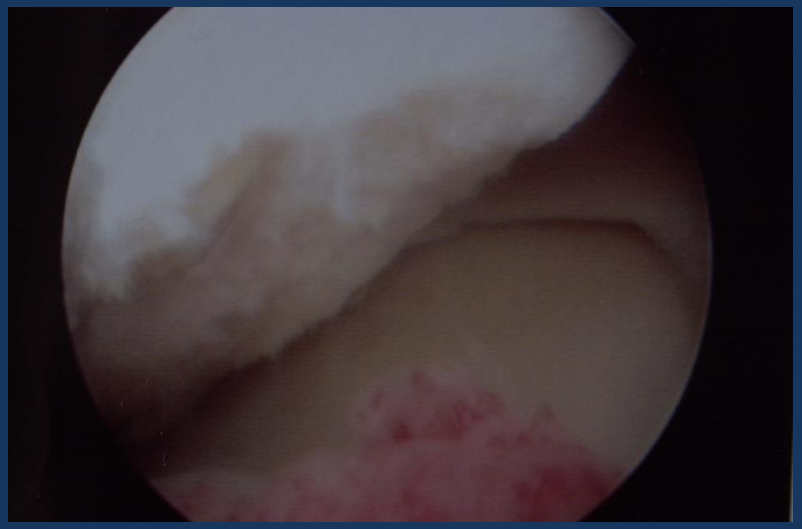

# CONDYLE LESION POSTOPERATIVE CARE

- NO BRACING
- FULL ROM
- NO WEIGHTBEARING 4/6 W
- THEN PROGRESSIVE WB

# WEIGHT BEARING

- JOINT LOADING INFLUENCES CHONDROCYTE FUNCTION BENEFICIALLY OR DETRIMENTALLY OVER A VERY BROAD RANGE AND IS AN IMPORTANT PART OF ANY REPAIR, REPLACEMENT, OR REGENERATIVE PROCESS

Jackson DW1, Scheer MJ, Simon TM **"Cartilage substitutes: overview of basic science and treatment options"** J Am Acad Orthop Surg. 2001 Jan-Feb;9(1):37-52

# CHONDRAL KNEE LESIONS
## THE ROLE OF THE PATELLA

Several anatomic predispositions may increase the risk of patellar dislocation and consequent chondral lesions:

- patella alta
- malalignement of the extensor mechanism
- increased Q-angle
- genu valgum
- shallow trochlear groove

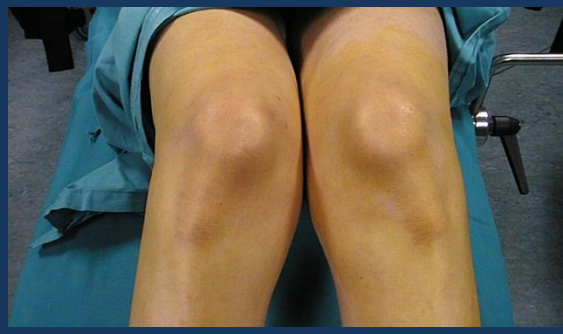

Kepler CK, Bogner EA, Hammoud S, Malcolmson G, Potter HG, Green DW. **"Zone of injury of the medial patellofemoral ligament after acute patellar dislocation in children and adolescents"** Am J Sports Med. 2011;39(7):1444-9

# PATELLAR LESIONS

- ARTHROSCOPIC DEBRIDEMENT AND CURETTAGE
- REFIXATION OF FRAGMENTS LESS EFFECTIVE

**AFTER SURGERY:**

- WEIGHT BEARING ALLOWED
- FLEXION LIMITATION

# BEST MANAGEMENT?

- IMMOBILIZATION
- EXCESSIVE SOLICITATIONS

→ LOSS OF GLYCOSAMINOGLICANS

→ CHONDRAL DAMAGE

(KIVIRANTA,1994 AROKOSKI,1993)

# RETURN TO SPORTS

MULTIDISCIPLINARY APPROACH

- SURGEON
- TEAM DOCTOR
- PHYSIOTHERAPIST
- TRAINER

PERSONALIZED
PROGRESSIVE
CHECHED

# RETURN TO SPORTS

**FIRST STEP**

- PROGRESSIVE WEIGHT BEARING
- ROM RECOVERY

**NO SWELLING**
**NO PAIN**
**FULL EXTENSION**
**NORMAL WALKING**

# RETURN TO SPORTS

**SECOND STEP**

- INCREASING WEIGHTS
- AEROBICS

**NO PAIN**
**FULL ROM**
**MUSCLE RESTORATION**

# RETURN TO SPORTS

**THIRD STEP**

- MOTOR SKILLS
- FULL ROM
- MUSCLE PERFORMANCE RECOVERY

**RUNNING 8 KM/H 10 MIN**
**MUSCULAR PERFORMANCE 80%**

# RETURN TO SPORTS

**FOURTH STEP**

- SPORTS SPECIFIC TRAINING
- MOTOR SKILLS

**RUNNING 8 KM/H 10 MIN**
**MUSCULAR PERFORMANCE 80%**

# AGE: 12 year old girl

Osteochondral lesion medial condyle

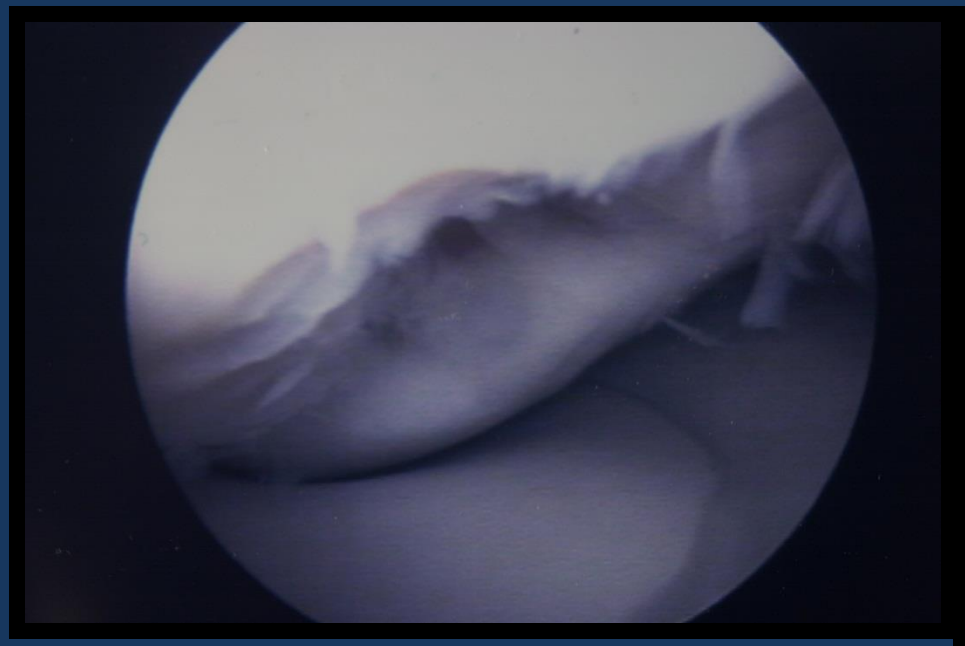

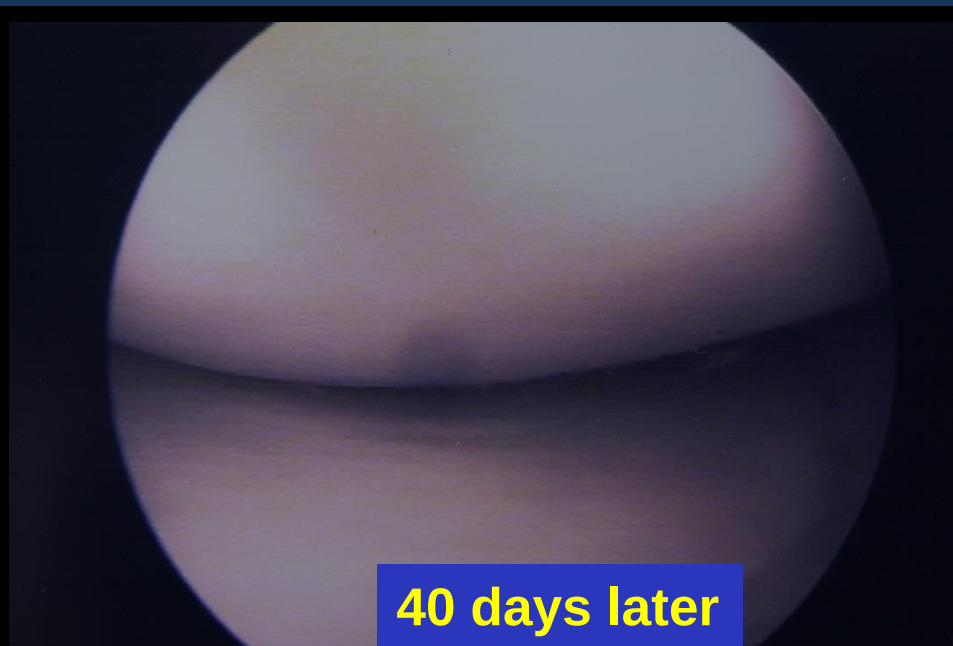

40 days later

# CF 49 y

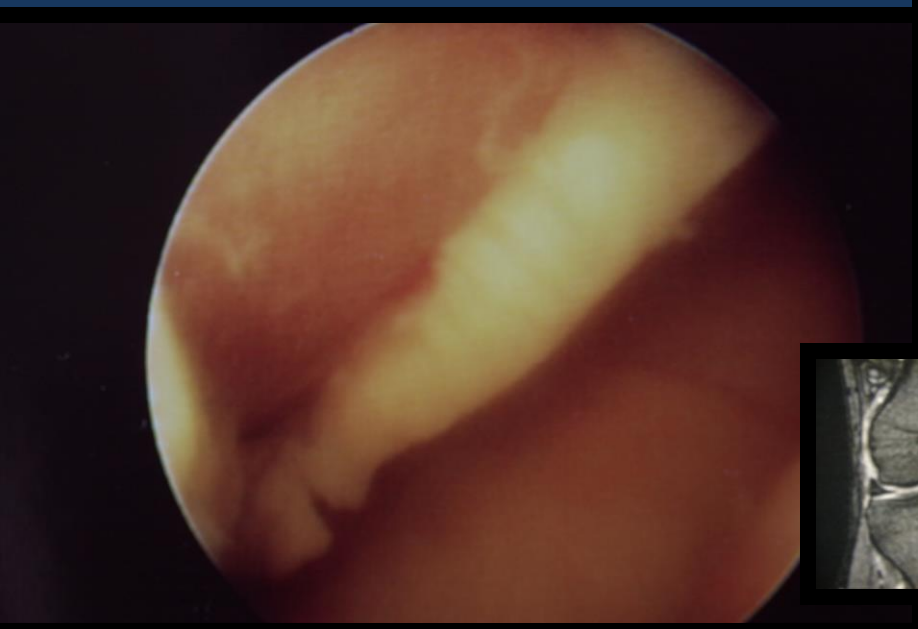

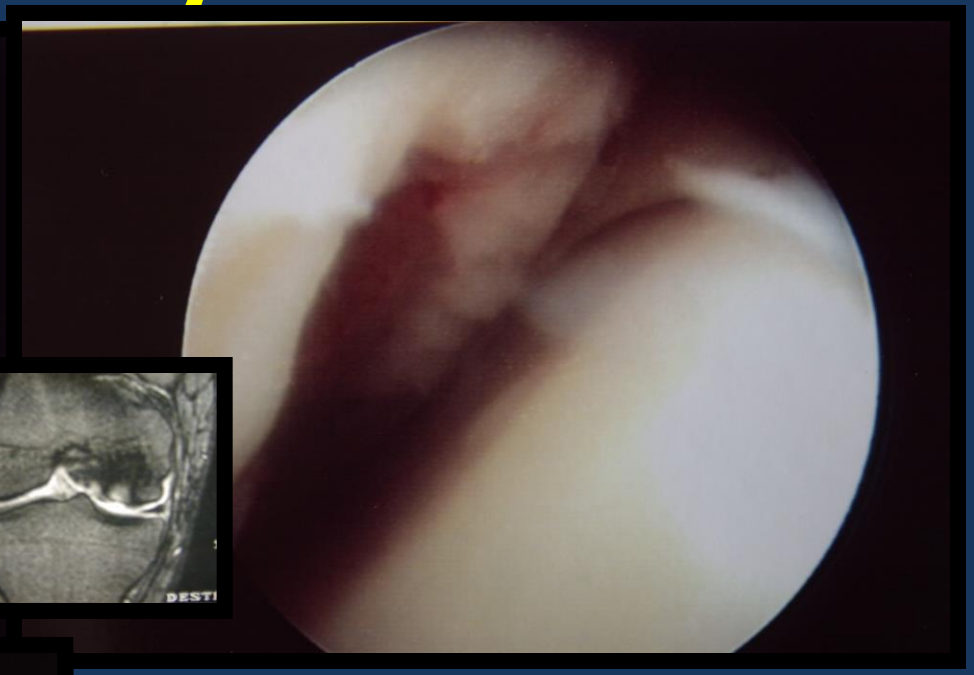

**Second look one year after debridement**
**No symptoms at 5 y**
**Quality of repair tissue?**


**2005 VU 63 y LEFT KNEE**
**pain on the lateral side**
**Debridement and lateral release**

# 7 y later, now 70
# Italian champion 300 m hs 2011

- **Indoor Italian Master  Championships 2012**


# Conclusions

- Specific phased rehabilitation according to:
- Individual lesions
- Surgical repair techniques
- Activity level
- Individual biology

**PAIN FREE!**

# TAKE HOME MESSAGES

- Techniques with a faster return to sports
- Take care of the associated lesions
- Early treatment of symptomatic lesions
- Less invasive techniques still preferred: microfractures , micro drilling
- Personalized treatment

**PAIN FREE!**

European Federation of National Associations of Orthopaedic Sports Traumatology

EFOST

Towards New Horizons with Enthusiasm

27-28 NOVEMBRE 2015
TORINO
8th EFOST CONGRESS 2015

# TORINO INTERNATIONAL CONGRESS ON SPORTS TRAUMATOLOGY

8 CREDITI ECM
20 CREDITI ECM CORSO FAD: "MANAGEMENT DELLE LESIONI SPORTIVE"

PRESIDENTI
GIAN LUIGI CANATA - GERNOT FELMET

TORINO2015
CAPITALE EUROPEA DELLO SPORT

POLITECNICO DI TORINO
CORSO DUCA DEGLI ABRUZZI 20
TORINO

SCIENTIFIC PROGRAM AND REGISTRATION ON
WWW.EFOST2015.ORG

SPONSOR

DePuy Synthes
tekka
ZIMMER BIOMET
BioTis
amedrix

## PROGRAMMA SCIENTIFICO

Topics
- LCA: anatomia, biomeccanica, indicazioni chirurgiche
- Lesioni legamentose multiple del ginocchio
- LCA: lesioni associate e revisioni
- Infiltrazioni in traumatologia dello sport nel 2015
- Ricostruzione del LCA all-inside
- Ritorno allo sport dopo la ricostruzione del LCA
- Spalla e gomito nello sport
- Nutrizione, endocrinologia e sport
- Trattamento delle lesioni meniscali nel 2015
- Anca e sport
- Acido ialuronico e PRP nel 2015
- Cartilagine nel 2015
- Protesi al ginocchio e sport
- Caviglia
- Prevenzione delle lesioni da sovraccarico nello sport
- Disabilità e sport
- Stato dell'arte nella traumatologia scheletrica sportiva
- Come valutare le lesioni di ginocchio
- Tecnologia e ingegneria nello sport
- Riabilitazione dei traumi sportivi
- Management delle lesioni nell'atleta top level
- Traumatologia sportiva del polso
- Diagnostica per immagini dei traumi sportivi

## SESSIONI SPECIALI – WORSKSHOPS – LETTURE – TAVOLE ROTONDE – FREE PAPERS

## BENVENUTI A TORINO

UN TERRITORIO, INFINITE EMOZIONI
La prima Capitale dell'Italia ti invita a scoprire la sua storia antica e moderna, i palazzi e i musei, i parchi e i viali alberati, il fiume e le alture, i ristoranti e i caffè storici, le lunghe vie porticate e i quartieri multietnici, i grandi eventi e i tanti piccoli piaceri che da sempre la rendono unica, in equilibrio tra la razionale urbanistica romana, il misurato sfarzo del barocco piemontese e l'originalità dell'architettura moderna e contemporanea.



ESSKA
ICRS
Città di Torino
REGIONE PIEMONTE
TORINO2015